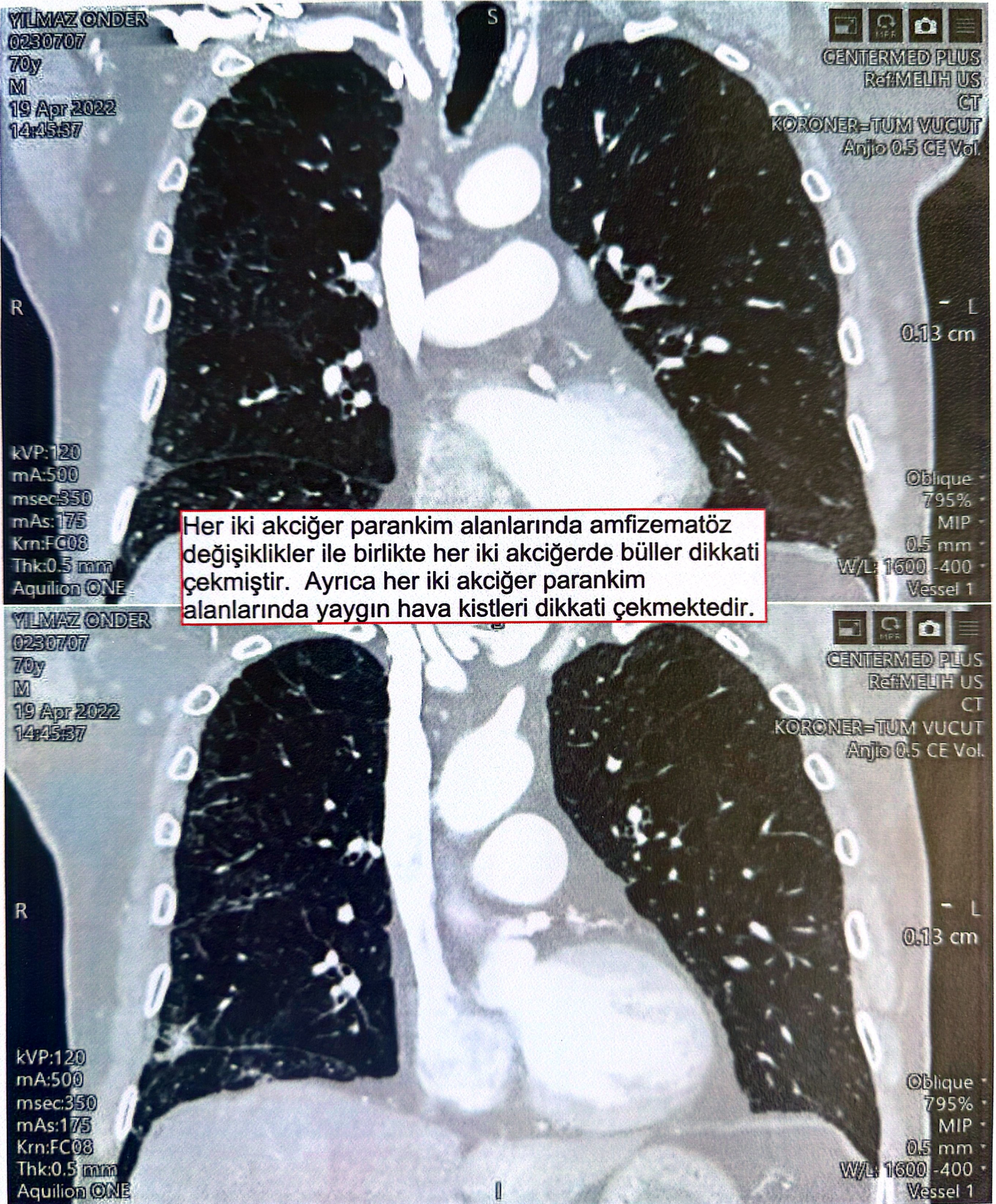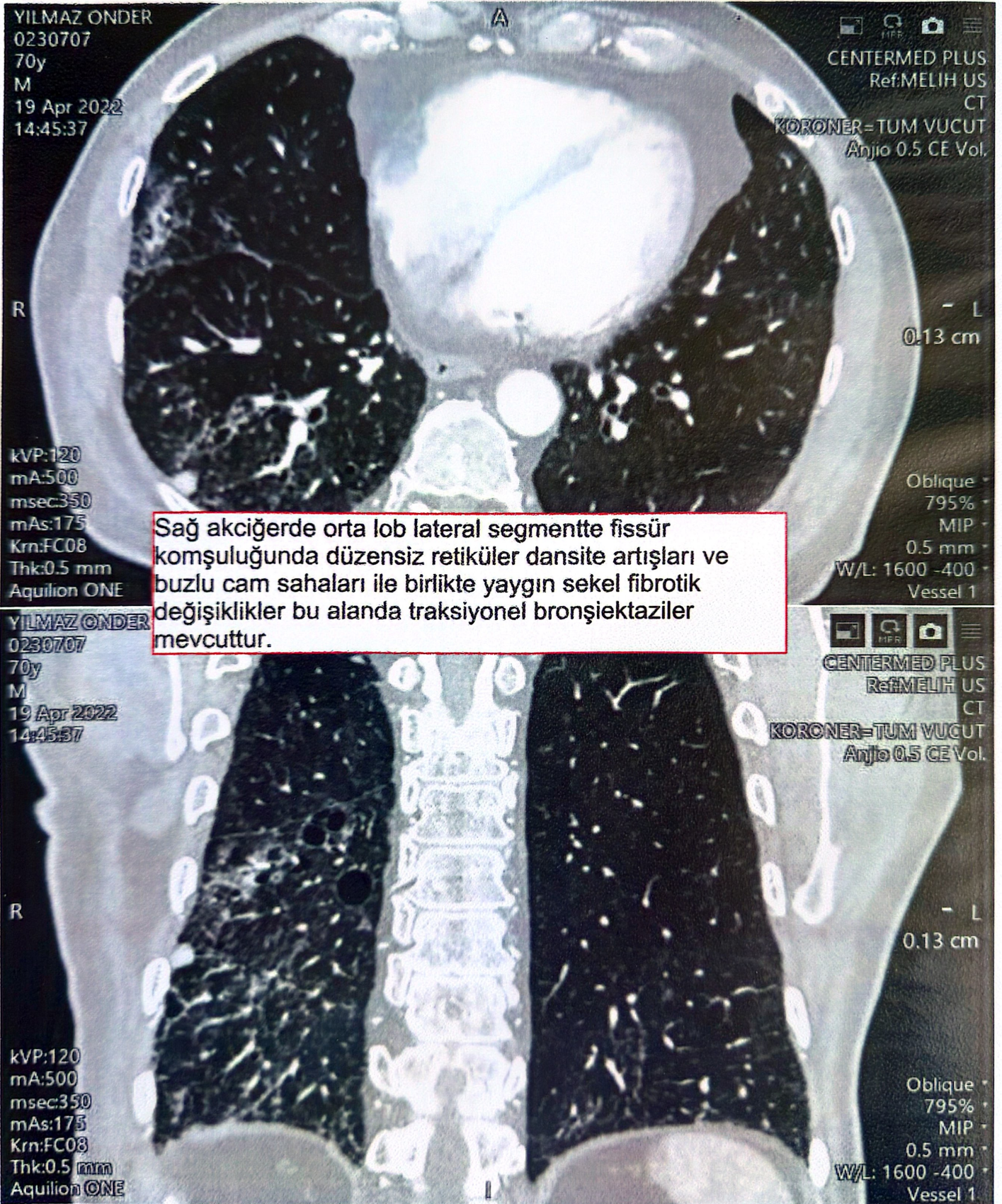
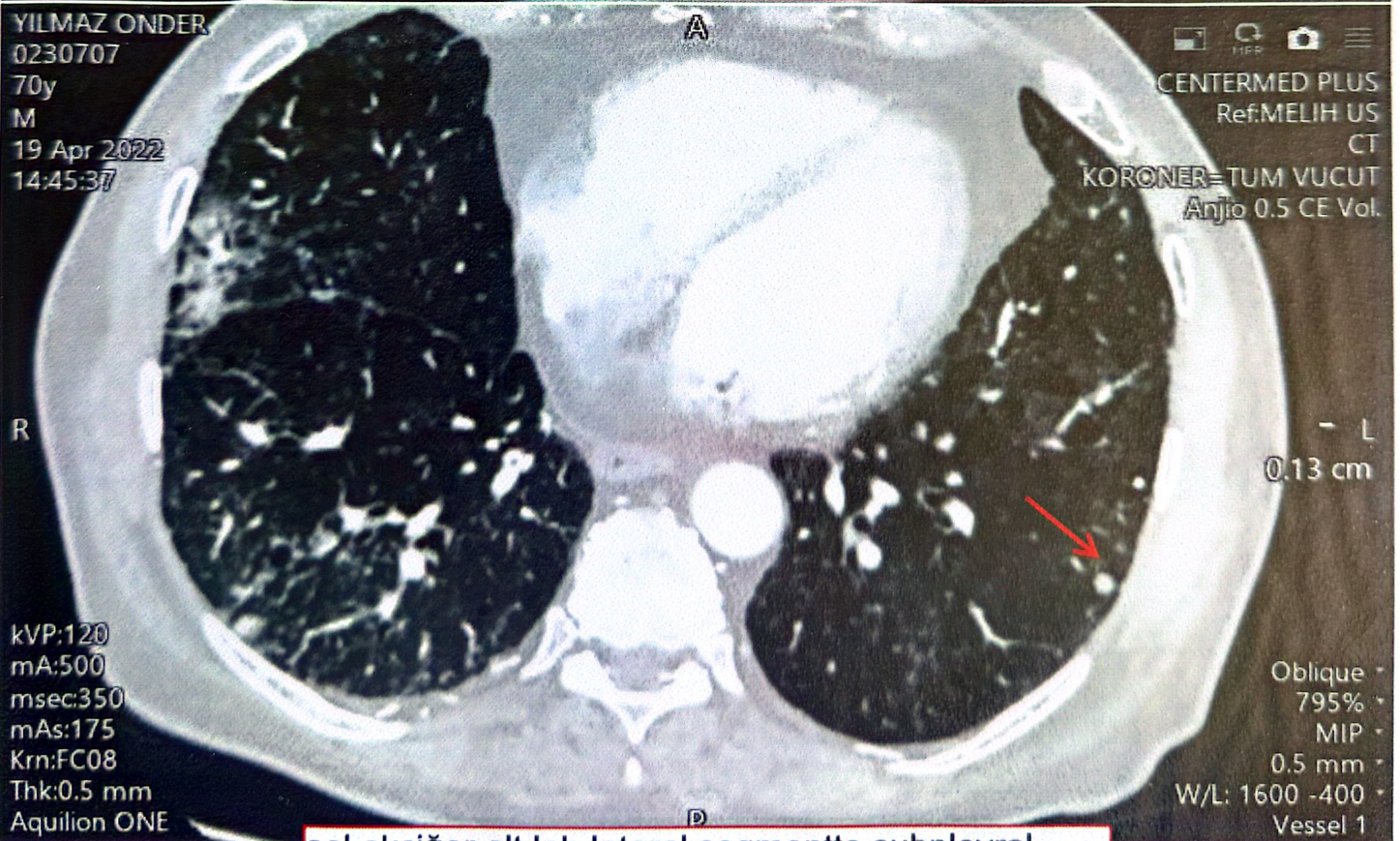
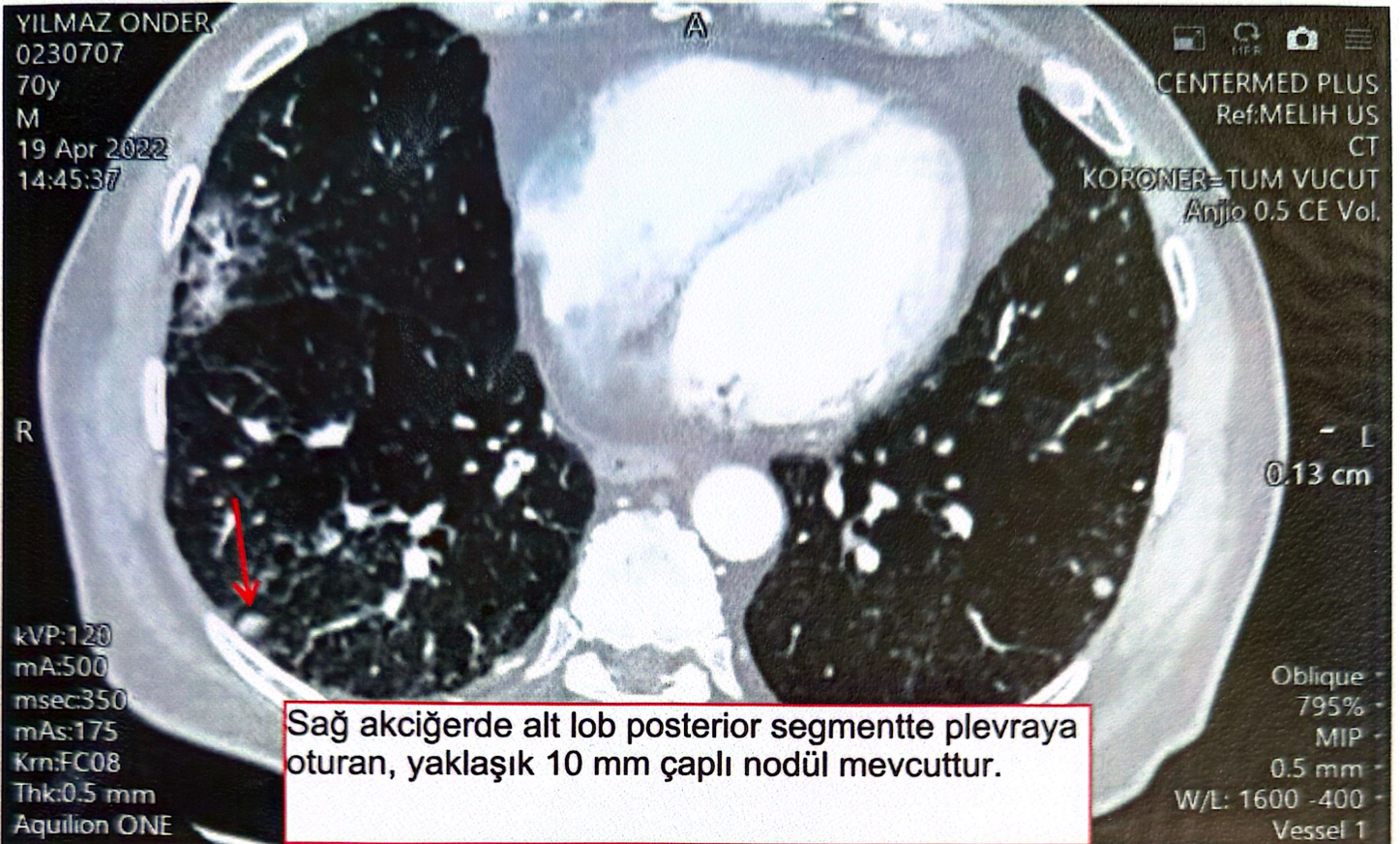
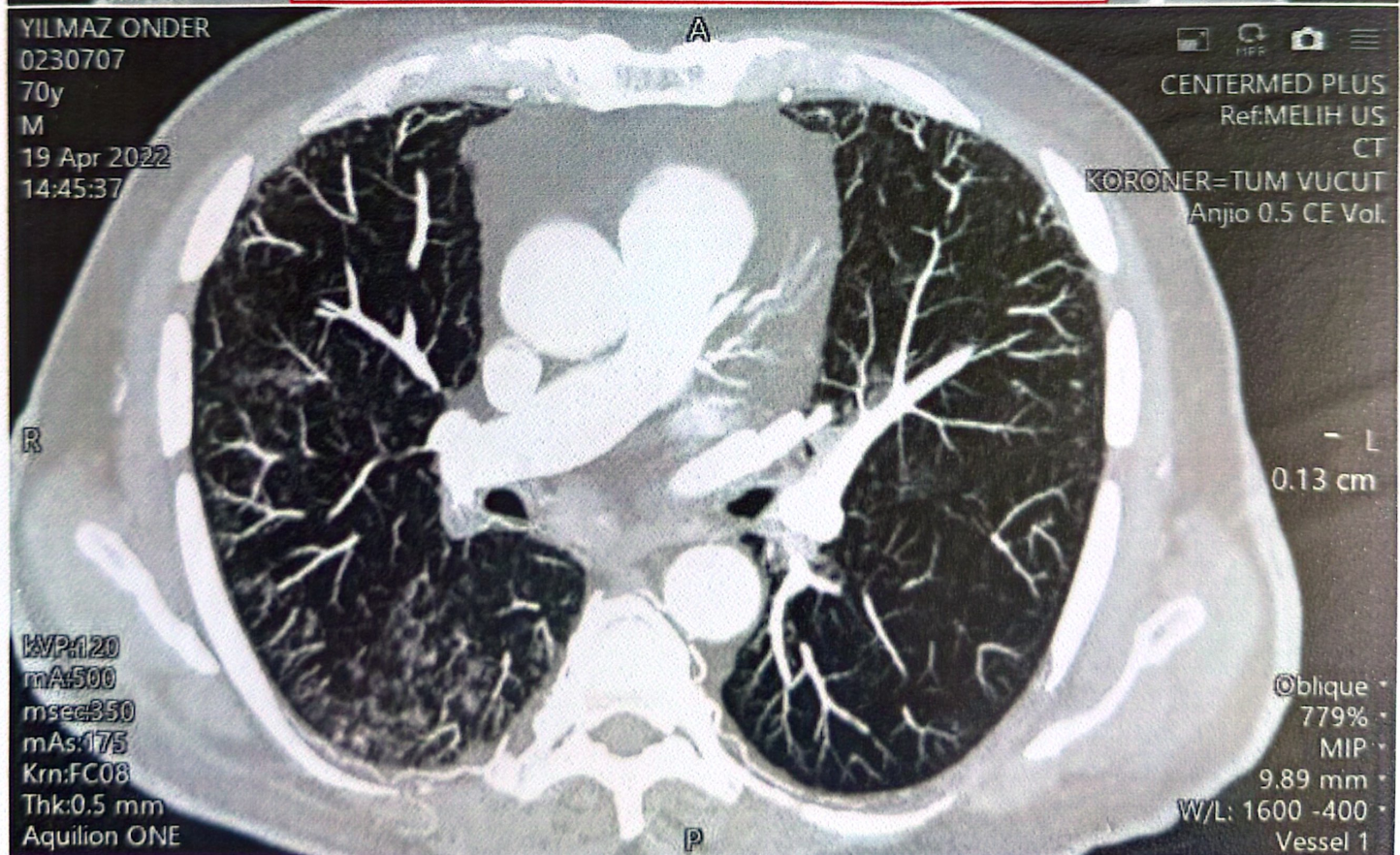
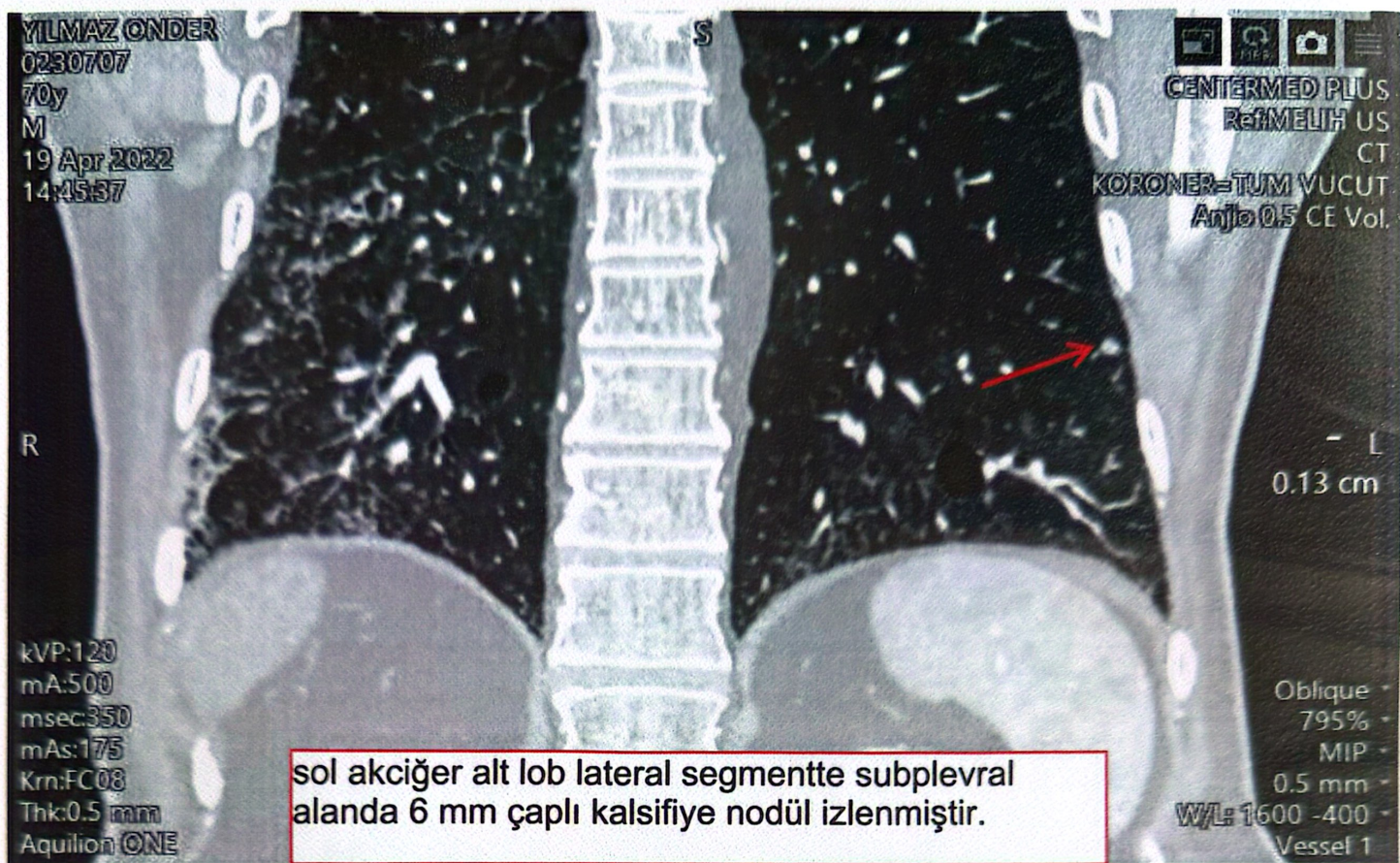
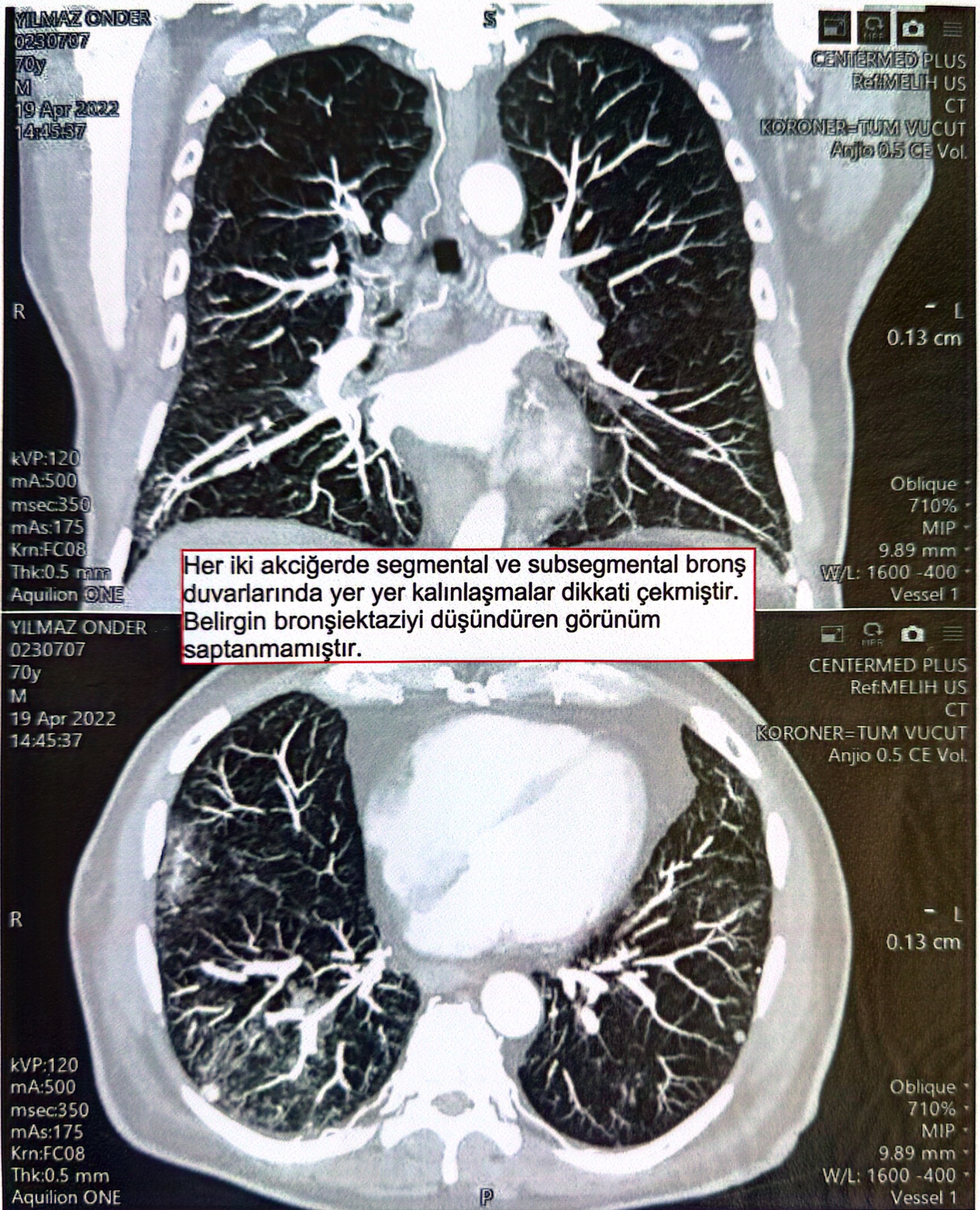


Patient: YILMAZ ONDER Page: 20 of 44



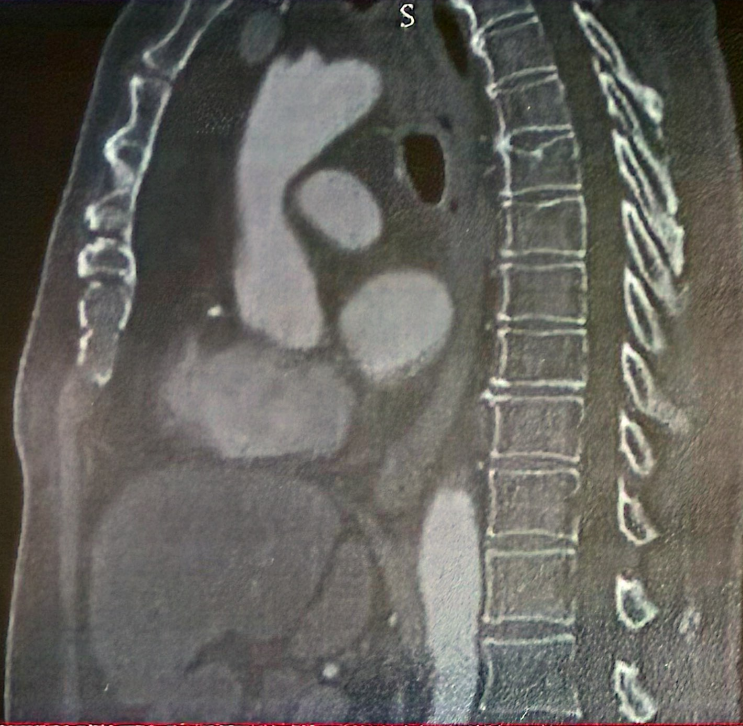





Patient: YILMAZ ONDER Page: 24 of 44

YILMAZ ONDER
0230707
70y
M
19 Apr 2022
14:45:37



A

kVP:120
mA:500
msec:350
mAs:175
Krn:FC08
Thk:0.5 mm
Aquilion ONE

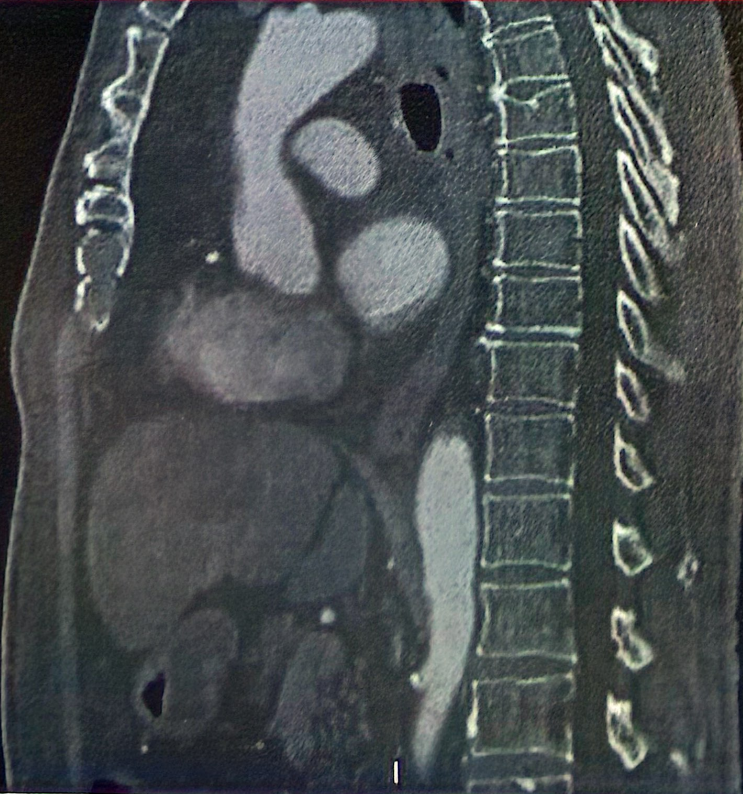Torakal vertebraların korpus yükseklikleri ve dansiteleri korunmuş olup torakal vertebra korpus köşelerinde yer yer köprüleşmeye giden osteofit gelişimleri mevcuttur.

CENTERMED PLUS
Ref:MELIH US
CT
KORONER=TUM VUCUT
Anjio 0.5 CE Vol.

- P
0.25 cm

Oblique ▾
584% ▾
MIP ▾
0.5 mm ▾
W/L: 3000 350 ▾
Vessel 1 ▾

YILMAZ ONDER
0230707
70y
M
19 Apr 2022
14:45:37



A

kVP:120
mA:500
msec:350
mAs:175
Krn:FC08
Thk:0.5 mm
Aquilion ONE

CENTERMED PLUS
Ref:MELIH US
CT
KORONER=TUM VUCUT
Anjio 0.5 CE Vol.

- P
0.25 cm

Oblique ▾
584% ▾
MIP ▾
0.5 mm ▾
W/L: 3000 350 ▾
Vessel 1 ▾